

RICKETS IN SUDANESE CHILDREN

By

MAHMOUD MOHD. HASSAN, M.D., F.R.C.P. (Ed),

F.R.C.P. (Glasg.) F.A.A.P., D.C.H.

Senior Consultant Paediatrician

KHARTOUM-SUDAN

The following types of Rickets were seen in Sudanese Children :—

1. Vitamin D- deficiency of Infantile Rickets. (V. rare)
2. Rickets associated with Protein-calorie malnutrition. (Uncommon)
3. Hypophosphataemic Rickets. (Common)
4. Renal Osteodystrophy (Renal Rickets) (Uncommon)
5. De. Toni-Fanconi Syndrome. (Rare).

1. *Vitamin D-Deficiency or Infantile Rickets:*

This is extremely rare in the Sudan owing to the availability of sun-shine throughout the year.

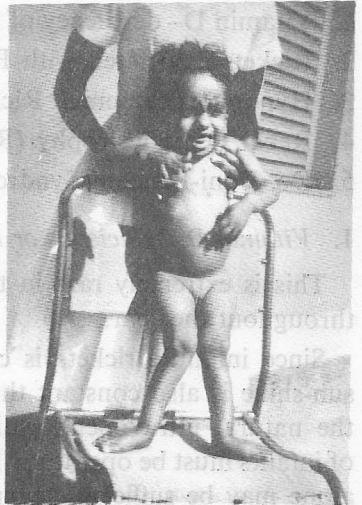

Since infantile rickets is common in some other African countries where sun-shine is also constant throughout the year, other factors, which obstruct the natural ultraviolet irradiation e.g. crowded housing and overprotection of infants must be operating. It is now almost agreed that ultraviolet irradiation alone may be sufficient to prevent rickets. Dietary sources of vitamin D are only required when a child is shielded from effective sunshine by clothing, housing conditions, or industrial smog. (Stamp, 1973).

In the Sudan, sun-shine is constant throughout the year. The predominant use of simple housing with plenty of open-air space and the use of light clothing to children owing to the hot weather have made sun-shine irradiation quite effective in preventing rickets.

During the last 15 years only two cases of vitamin-D deficiency rickets were seen, both induced by environmental factors :—

1. A male infant, aged 9 months, the last born baby after a series of nine girls, showed the manifestations of rickets, The main precipitating factor was over-protection by the mother because of fear of illness and evil eye. He recovered with vitamin D therapy and exposure to sun-light.

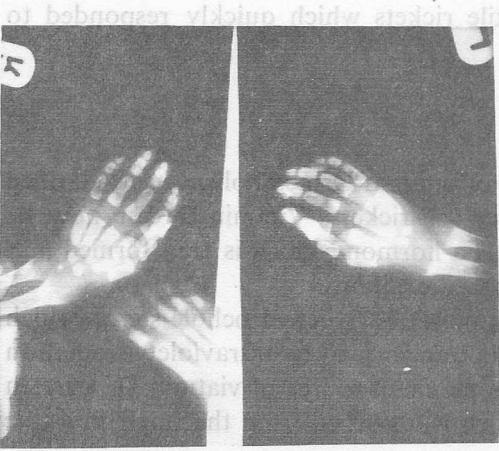
2. A girl, aged 10 months, who was referred to me from a district hospital, where she was kept indoors for 6 months because of severe haemolytic anaemia:



The following types of Rickets were observed:

1. A male infant, aged 9 months, the first-born baby after a series of nine girls, showed the manifestations of the main precipitating factor was over-protection by the mother, over-feeding, and lack of sunlight. He recovered with vitamin D therapy and sunlight.

2. A girl, aged 10 months, who came from a district hospital, where she was kept indoors for 6 months because of severe haemolytic anaemia.

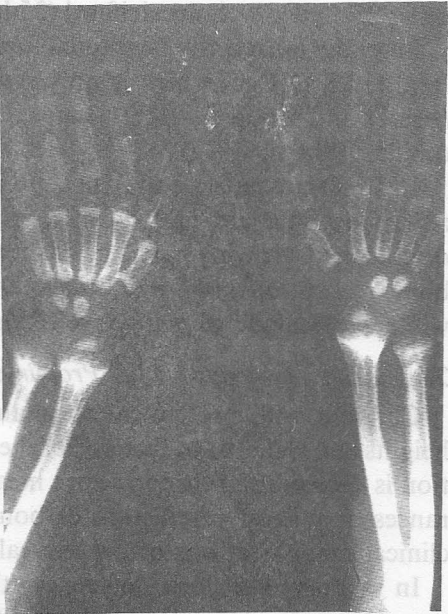


The showed manifestations of infantile rickets which quickly responded to treatment.

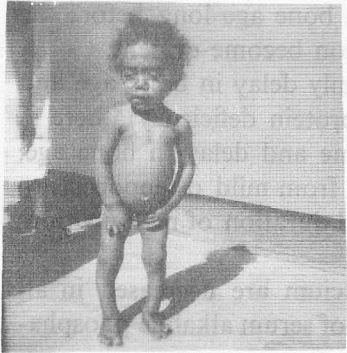DISCUSSION:

Vitamin-D Metabolism:
 Recent discoveries of the pathways the etiology of many obscure aspects considered not only as a vitamin but a number of metabolites which have The physiological precursor of vitamin D is synthesized in the skin and liver to cholecalciferol (vitamin D₃). This is fish oils are rich in cholecalciferol in the presence of bile salts.

By the use of isotopes, the synthesis in the liver of an active vitamin-D metabolite (1,25-dihydroxycholecalciferol) was demonstrated (De Luca, 1969).
 Vitamin-D 1,25-dihydroxycholecalciferol was discovered. It is synthesized by the kidney. It was shown to be synthesized in the renal tubules in intestinal calcium absorption. Calcium hydroxyapatite in calcifying tissue at the rate of 1.25 DH cc causes far more increased than 25 H cc and parathyroid hormone. (De Luca et al, 1972).



Protein Malnutrition:
 Protein malnutrition is physically retarded both in weight and height. The early features of protein-calorie malnutrition are: (1) Radiological appearance of the bones is similar to that of rickets.



Protein-calorie malnutrition is a common cause of rickets. It is characterized by a wide spectrum of osseous manifestations ranging from mild osteoporosis, deformity in the shape and size of bones and delayed ossification to frank rickets changes, depending on the severity and duration of the malnutrition. Biochemical findings: (Table I) The levels of calcium and phosphorus in 70 per cent of cases. The levels of calcium and phosphorus can be observed.

She showed manifestations of infantile rickets which quickly responded to treatment.

DISCUSSION:

Vitamin-D Metabolism:

Recent discoveries of the pathways of vitamin-D metabolism have clarified the aetiology of many obscure aspects of rickets. Vitamin-D can now be considered not only as a vitamin but as a hormone which is transformed into a number of metabolites which have specific actions.

The physiological precursor of vitamin-D is 7-dehydrocholesterol which is synthesized in the skin and liver. It is transformed by ultraviolet irradiation to cholecalciferol (vitamin D₃). This is the main source of vitamin D. Certain fish oils are rich in cholecalciferol which is absorbed from the small intestine in the presence of bile salts.

By the use of isotopes, the synthesis in the liver of an active vitamin-D metabolite; 25-hydroxycholecalciferol (25 Hcc) was demonstrated (De Luca, 1969).

Later the most active hormonal form of vitamin-D 1,25-dihydroxycholecalciferol (1,25 DH cc) which is only synthesized by the kidney, was discovered. (Fraser and Kodicek, 1970). Later it was shown to be synthesized in the renal tubules (Shain, 1972).

1,25 HD cc exerts a powerful action in intestinal calcium absorption. Calcium and phosphate are laid down as hydroxyapatite in calcifying tissue at the osteoid and growing cartilage of bone. 1,25 DH cc causes far more increased bone resorption (100-fold times) than 25 H cc and parathyroid hormone, while cholecalciferol is inactive (Raisz et al, 1972).

2. Rickets Associated with Protein-calorie Malnutrition:

Children with protein-calorie malnutrition are physically retarded both in heights and weights. In fact one of the early features of protein-calorie malnutrition is decreased anthropometric measurements. (table 1). Radiological appearances may show rarefaction of bone and delay in bone age long before the clinical manifestations of protein-calorie malnutrition become evident.

In marasmus (calorie-deficiency) there is commonly delay in bone age and retardation in skeletal growth. In Kwashiorkor (protein deficiency) there is osteoporosis, deformity in the shape and size of bone and delay in bone age. A wide spectrum of osseous manifestations ranging from mild osteoporosis to frank rickety changes, depending on the severity and duration of malnutrition, can be observed.

Biochemical findings: (Table 1) The levels of calcium are decreased in all cases; phosphorus in 70 per cent of cases. The levels of serum alkaline phosphatase

tase in 80 per cent of cases are lower than the upper level of normal unlike pure vitamin-D deficiency rickets.

After treatment with high protein diet, the bones become normal in appearance and the levels of calcium, phosphorus and alkaline phosphatase increased to normal levels. The children were exposed to sun-light, but vitamin-D was not administered.

Aetiology:

The basic defects lie in (a) protein deficiency leading to defective synthesis of osteoids, the organic matrix. (b) hepatic dysfunction leading to defective synthesis of 25 Hcc.

3. *Hypophosphataemic Rickets:*

This is the commonest type of rickets in the Sudan .It is commonly familial, but sporadic cases occur. I have 12 cases in record. In the first 7 cases reported, (Hassan, M.M. 1966) (table 2), the first 3 cases belonged to one family. The other 5 cases also occurred in another family.

Genetics:

In the familial cases a dominant sex-linked mode of inheritance is observed with complete penetrance of hypophosphataemia, which is constant in all cases.

The osseous ricketic changes are more severe in all patients. Craniosynostosis has been described in some cases. One of my cases has scaphocephaly.

Associated alopecia totalis, which occurred in one family (recorded below) has not been described previously.

Aetiology:

The underlying aetiological lesion is not yet confirmed A number of theories were proposed:—

1. *Primary lesion in the renal tubule:*

Hypophosphataemia depends on intrinsic renal tubular defect to reabsorb phosphate, leading to hyperphosphaturia.

2. *Intestinal malabsorption of calcium:*

The parathyroid is stimulated by calcium deficit leading to secondary hyperparathyroidism and hyperphosphaturia.

The objections to this theory are :—

- (a) Lack of radiological evidence of hyperparathyroidism.
- (b) The serum calcium is normal in most untreated cases —.

3. *The role of magnesium:*

Recently two cases of magnesium dependent vitamin-D resistant rickets

were described (Reddy, V and Sivakumcer, B 1974). The serum calcium in both cases were lower than normal. 7.2 and 7.3 mg per 100 m, and there was hypophosphataemia, 1.7 and 3.6 mg. per 100 ml. Both cases did not respond to massive doses of vitamin D. Serum magnesium was found low in both cases, (0.5 mg per 100 ml, and 0.74 mg per 100 ml). After administration of magnesium chloride supplements in addition to large doses of vitamin D dramatic improvement occurred.

It is postulated that 25 -hydroxylation of vitamin D may be magnesium dependent (Rosler and Rabinowitz, 1973). In the case recorded below, the level of magnesium was normal.

4. Defective conversion of vitamin-D to 1,25 - dihydroxycholecalciferol. 1.25 DH cc is synthesized by the kidney in the renal tubules. It is the most active metabolite of vitamin D. It exerts a powerful action in intestinal calcium absorption.

Its defective synthesis seems to me the most likely aetiological factor in this syndrome.

Case Record:

A.M.O. female aged 14 months presented with swellings of wrists, ankles, muscular weakness and loss of hair for 5 months. *Family history:*

Mother, aged 36 years; father 50. Both enjoy good health. They had 6 children, 2 still-births and 5 abortions. The first child, a girl, aged 16 years, and the fourth child, a boy aged 10 years, are normal. They have both good hair. All 4 other children lost their hair at about the age of 6 months, showed manifestation of rickets at the age of 1- years and died of intercurrent infection at about the age of 2 years.

Examination showed a bright girl, with complete alopecia and there were osseous manifestations of rickets.

Head circumference was 47 cms. (18.8. inches) height 64 cms, (25.6 inches), weight 15 Ib. (7 kg.) Mid-arm circumference 14- cms. and mid-thigh 24- cm. Teeth were hypoplastic.

Investigations:

Serum calcium	4.3 m., EQ/litre. (8.6 mg/100 ml) serum
Inorganic phosphates	- 2.2 mg/100ml.
Total proteins	- 8.1 gm/100ml.
Albumin	- 4.7 gm/100ml.
Globulins	- 3.4 g /100ml.
Alkaline phosphatase	- 88K.A. units.
Serum magnesium	- 2.5 mg/100ml.
(Spare's method: Normal	1.8-2.9 mg/100ml.)

Treatment:

She was given high doses of vitamin-D 10,000 units daily for 2 months without effect. Vitamin-D is gradually increased to 30,000 units daily.

4. *Renal Osteodystrophy ?Renal Rickets?*

Renal Osteodystrophy, is a complication of renal failure.

The commonest causes of renal hypofunction are :—

- (a) Chronic Glomerulonephritis
- (b) Pyelonephritis
- (c) Renal hypoplasia
- (d) Polycystic disease of the kidney.
- (e) Hydronephrosis.

The resulting chronic glomerular and tubular insufficiency lead to acidosis and hyperphosphatemia. In the light of the present conception of vitamin-D, the most likely cause is defective synthesis of 1,25 DH cc.

Case Record:

N.A., a male, was admitted at the age of one year in the chest hospital as a case of respiratory infection. After discharge from hospital he suffered from thirst and polyuria and he was admitted to the children department of Khartoum Hospital as a case of acute renal failure. The child recovered after a storming period, He was readmitted at the age of 3 years with signs of renal osteodystrophy Genu valgum and typical signs of rickets. X-ray showed Osteoporosis and osteolytic lesions.

Investigations:

Serum Calcium	– 9.8 mg/100ml.
Serum phosphours	– 6.9 mg/100ml.
Serum Alkaline	– 30 K.A. units
Blood Urea	– 30 mg/100ml. and gradually increased to 120 and 275 mg/100 ml, when he developed uraemia.

Intravenous pyelograms and renograms showed renal hypoplasia. Calciferol 25,000 units a day and increased to 50,000 caused only slight healing.

Osteotomy was performed but it gave only mild improvement in the bony deformities.

5. *De-Toni-Fanconi Syndrome:*

The syndrome comprises a variety of proximal renal tubular defects, which show typical histological changes described as “Swan neck” because of its abnormally narrow segment. The abnormal findings in plasma and urine, i.e. aminoaciduria, renal glycosuria, hypophosphataemia and hyperphosphaturia

result from decreased tubular reabsorption of phosphate, glucose and aminoacids. Aetiology :- Defective synthesis of 1,25 DH CC provides the most likely explanation for the rickety changes in this syndrome.

Treatment:

Large doses of vitamin-D (25,000-1000,000 I.V daily) may cause some improvement of osteomalacia. Surgical correction is needed in these cases.

Case Record:

A.H.A., aged 10 years admitted to children department Khartoum Hospital on 2.3.1974 because of inability to walk and pain in both knees and back for the last 2 years. Osteotomy of medial upper third of both tibiae was performed in Gada Hospital a year previously. No marked improvement resulted since then.

On Examination:

Patient looked physically weak. Mentality was normal. He was not anaemic, nor jaundiced. Pulse 88 per min. B.P. 100/65. He had pigeon-chest deformity and slightly enlarged costo-chondral junctions. There were enlargements of the lower ends of radii ulnae, femours, and upper and lower end of the tibiae.

Patient cannot stand without full support. Other systems were normal.

Investigations:

General urine analysis showed albuminuria and glycosuria Specific gravity 1008. No Acetone was detected.

Urine chromatography showed generalized aminoaciduria.

Urine urea - 44 mg/100ml.

Blood sugar - 2 hours after meal - 52 mg/100 ml.

Hb. - 13.8 g/100ml.

PCV - 40 per cent.

W.B.C. - 6600/ml.

Polymorphis 52%

Lymnocytes 41%

Monocytes 5%

Eosinophils 2%

Blood smear showed normchromic, normocytic.

Red blood chells. Platelets were normal.

E.S.R. - 58 mm/hour

Serum calcium - 4.0 Eq./l (8mg/100 ml)

Serum phosphorus - 3.1 mg/100 ml.

Serum alkaline phosphatase - 41.4 K.A. units.

Serum Sodium - 134m Eq/l.

No	Name	Age in months	Sex	Wt. lb.	Ht. cms	Diagnosis	Serum Ca mg/100ml'	Serum ph mg/100ml	alkalin ph-ph-K. A.un.	Serum magnesium mg/100ml	Plasma protein gm/100	Albumin g/100ml	Globulin g/100ml	X-ray-bones
1	Hatim	30	M	16	75	Kwashiork.	8.8	4.3	14	3.0	4.8	1.8	3	severe Osteoporosis 3 faint Ep. centres.
2	Faiga	12	F	10	60	Kwashiork.	8.8	2.7	19	2.8	5.1	3.8	1.3	severe Osteoporosis No epiphyseal centre
3	Santue	27	M	14	71	Marasmus	9.1	3.7	21	2.9	6.4	4	2.4	Mild Osteoporosis 2 ep. centre
4	El Fayib	24	M	11	75	Marasmus	8.8	3.7	26	3.0	6.9	3	3.9	
5	Nagwa	18	F	14	70	Marasmic Kwashiork.	8.6	3.3	8	2.5	6	3.3	2.7	Mild Osteoporosis 3ep. centre
6	IS	1	F	15	70	Marasmic Kwashiork.	8.1	2.7	14	2.5	7.2	4.8	2.4	Mild Osteoporosis 3ep. centres
7	Tabani	4	F	7	53	Marasmus operated abesiss	8.5	4.0	19	1.9	6	3.4	2.6	
8	Badr	9	M	7	64	Marasmus	8.1	3.3	12	2.3	5.3	3.9	1.4	Osteoporosis 2ep. centres.
9	Mayi	14	F	3	68	Mild Mar.	8.8	5.0	14	3.2	7.4	3.3	4.1	No. ep. centres.
10	Abbas	24	M	11	67	Marasmus	8.9	4.0	12	3.2	6.4	4	2.4	Mild osteop 2Ep. centres.

TABLE I:
Rickets Associated with Protein Caloric Malnutrition Biochemical Investigations and Radiographs of Bones

Serum Potassium – 3.7m Eq/l.
Serum magnesium – 2.9 mg/100ml.
(spare's method normal 1.8 – 2.9).

Treatment:

He did not show improvement neither to high doese of vitamin-D nor to surgical correction. He is slightly improving with physiotherapy.

Conclusion:

Since vitamin-D deficiency rickets is uncommon in the Sudan, any case which present with rickey manifestations, is a challenging problem, the proper diagnosis of which needs proper study investigations.

When the new and powerful vitamin-D metabolites become available, effectiv therapeutic and the precise aetiology will be confirmed.

Acknowledgement:

I am grateful to Dr. Fadil Rabi, Ph.D., biochemistry department, Faculty of Medicine, Khartoum for urine chromatography..

REFERENCES

- Deluca, H.F. (1969) 25 hydroxycholecalciferol,
The probable metabolically active form of Vitamin D. American Journal of clinical
Nutrition, 22, 412.
- Hassan, M.M. (1966): Congenital retardation of growth in Sudanese children.
Sudan Medical Journal, Vol. 4 No. 4 P. 174.
- Raisz, L.G. Trummel, C.L., Holick, M.F., and Dehuca, H.F. (1972) 1,25 dihydroxychaleca-
lcalciferol: A patent stimulation of bone resouption in tissue culture. Science, 175,767.
- Shain S. (1972). In vitro metabolism of 25-hydroxycholecalciferol by clicc chick intestin-a
and renal cell. Preparation: Identification of a metabolic product as 1,25 – dihydroxyl
choleslciferol and delineation of its metabolic fate in intestinal cells. Journal of Biological
Chemistry, 247, 4393.
- Stamp. T.C.B. (1973): Vitamin D Metabolism. Archives of Disease in childhood, 48, 2.